



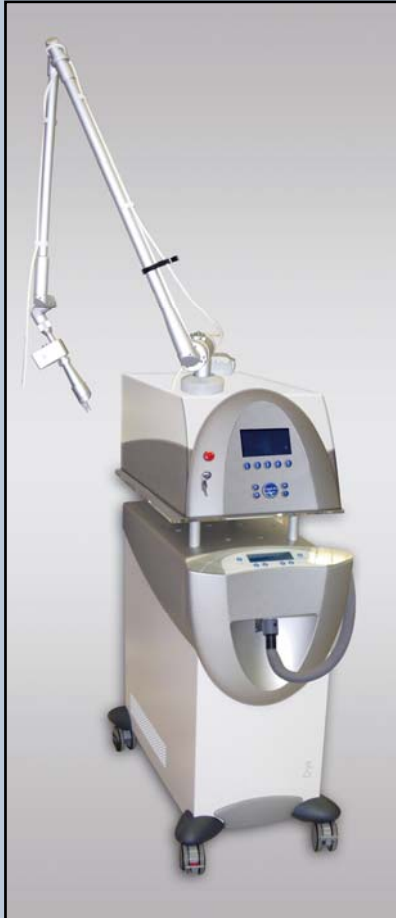
902293029

EXELO₂


Fotos de antes y después



Exelo2 : El láser CO2 Fraccionado




- Objetivos:
 - Reducir las arrugas
 - Crear micro-ablaciones puntuales
 - Inducir efectos térmico en la Dermis
 - Rejuvenece una fracción de la piel
 - La tonifica
 - Mejora su textura
 - Estimula la producción de colágeno
 - Revitaliza la dermis
 - Mejora las Cicatrices

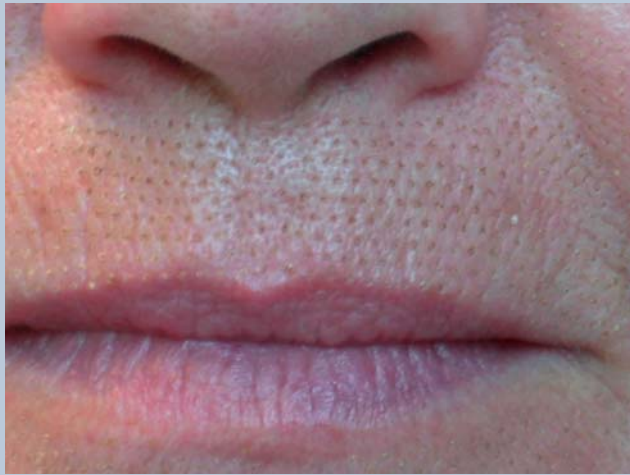

Technical characteristics

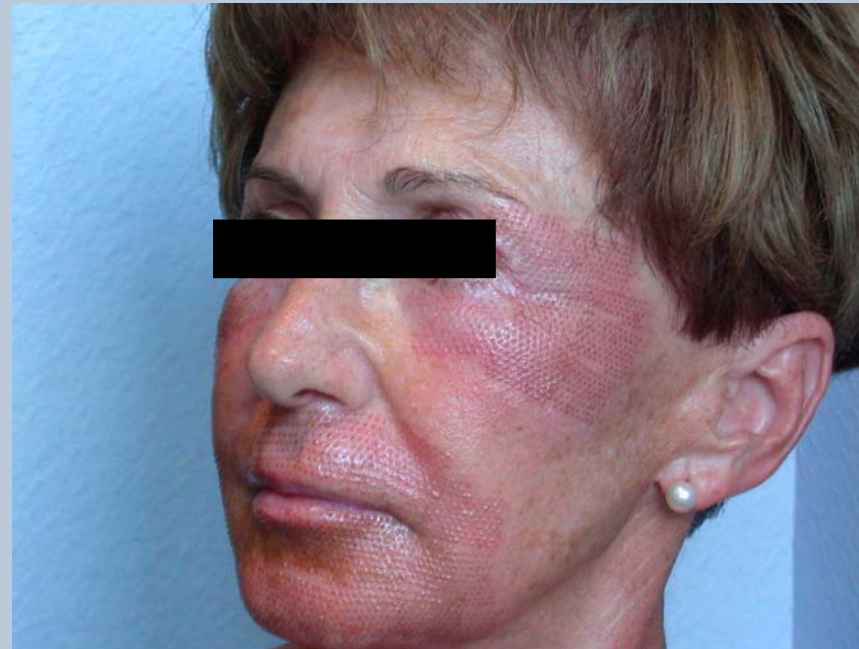- Laser CO2
- Longitud de onda 10.6 μm
- Potencia 30 W
- Duración de pulso 2 to 100ms, or CW
- Tamaño de spot 250 μm
- Area de tratamiento hasta 4 cm^2
- Refrigeración cutánea chorro de aire (opcional)
- Tamaño del equipo 34 * 65 * 27 cm^3
- Peso 33 kg




Efectos secundarios



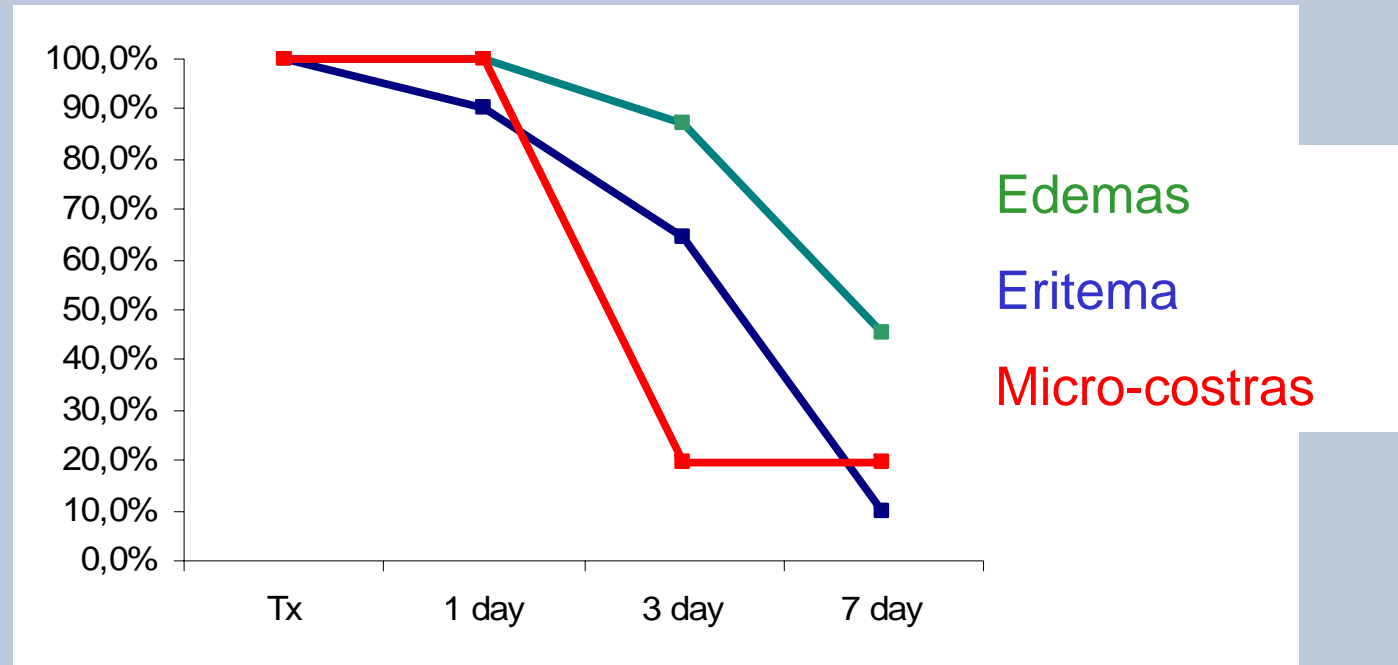
Efecto inmediato




Eritema post tratamiento 24 horas después



Efectos secundarios...evolución



Evolución de los efectos secundarios




Estudios clínicos

- Iniciado desde 2004 con el Dermatólogo J.L. Lévy, MD (Marseille, Fr)
- Estudio multicentro (ASLMS 2007)
 - Fractional Resurfacing combined with air cooling as a novel approach for skin tightening.
- Otros estudios
 - Multicenter study on the effects of the spots density (results & side effects). Toward an adapted treatment.
 - Melasma

Sylvie Angel, Dominique Boineau, Jean Luc Levy, Serge Mordon, Paris, Bordeaux, Marseille, Lille, France

Sylvie Angel, Dominique Boineau, Serge Mordon, Paris, Bordeaux, Marseille, Lille, France

Anne Kolbe, Ile de la Réunion, France



FRACTIONAL RESURFACING COMBINED WITH AIR COOLING AS A NOVEL APPROACH FOR SKIN TIGHTENING

Sylvie Angel, Dominique Boineau, Serge Mordon, Paris, Bordeaux, Lille, France

Introduction
 Facial rejuvenation using ablative methods is one of the most popular procedures in cosmetic surgery. CO₂ laser has been the gold standard for ablative resurfacing of the skin for many years. However side effects as downtime, pain or hyperpigmentation are negatively perceived from patients. A new approach which induces patterns of microspots of thermal damage in the skin in combination with air-cooling has been developed. Microthermal injuries with subsequent healing response have been recently proposed to induce neoelastogenesis. This study aimed to evaluate the efficacy of the new technique using clinical assessment over a 3-month period. The clinical efficacy, the duration of edema and redness were evaluated.

Results
 21 patients (17F & 4M; mean age: 59 ±1-12) were treated on different locations (periorbital, peri-orbital, full-face). Thanks to air cooling, pain was found to be tolerated by all patients. The pain level was moderate (2.6 ±1-1.2). Duration of edema, redness and crusting are reported in figure 1.

Materials & Methods
 A CO₂ laser prototype (Exelo2, Quantel Medical, France) providing a pattern of 250µm spots (density: 25-50 microspots/cm², power: 5-10W, pulse duration: 1000ms) was evaluated on the periorbital, perioral or full face area. 21 patients with phototypes II, III, IV and with Fitzpatrick elastosis score (1-9) received one to three treatments at 4-week interval.

All treatments were performed without topical anesthesia. Patients were asked to apply a healing cream (Ialucel™) several times a day, for 3 days after treatment. Patients and physicians graded the level of improvement using pre and post-treatment photographs. Edema and redness, crusting were evaluated at 1, 3 and 7 days post treatment. Pain (scale: 1-4) and Fitzpatrick's score reduction have been also evaluated. Treatments were performed in 2 independent laser centers in France.

Figure 1: Duration of redness, edema and crusting
 Bar chart showing duration of redness, edema, and crusting. Redness and edema are the highest, followed by crusting.

Figure 2: Before and after Fitzpatrick score at 3-month follow-up
 Bar chart showing Fitzpatrick score reduction. Scores are significantly lower at 3-month follow-up compared to before treatment.

Figure 3: Fitzpatrick's score reduction
 Bar chart showing Fitzpatrick's score reduction. Scores are significantly lower at 3-month follow-up compared to before treatment.

Figure 4: Satisfaction level of the patients at 3-month follow-up
 Pie chart showing satisfaction level. 90% of patients would recommend the treatment to a friend.

Clinical pictures
 A series of photographs showing skin improvement before and after treatment, including close-ups of the periorbital and perioral zones.

Conclusion
 This clinical study confirms that fractional resurfacing with the CO₂ laser combined with air-cooling is a safe, efficient and rapid procedure. A full-face treatment requires no preparation nor anesthesia and is performed in 20 minutes with a high level of patient satisfaction.

Background and Objectives

Facial rejuvenation using CO₂ laser has been the gold standard for ablative resurfacing of the skin for many years. However side effects are negatively perceived from patients. It has been recently proposed to induce well-controlled tightening through microexcavations surrounded by zones of microthermal injury to reduce the down-time associated with traditional ablative procedure.

A new approach which induces patterns of microspots of ablative and thermal damage zones in the skin in combination with air-cooling has been developed. This study aimed to evaluate the efficacy of this new technique using clinical assessment over a long term period. The clinical efficacy, the duration of edema and redness were evaluated at different densities of microspots/cm².

Study Design and Methods

A fractional CO₂ laser (Exelo2, Quantel Derma, France) providing a pattern of 250µm spots (power: 10W, pulse duration: 2ms and density: 100, 150 or 200 microspots/cm²) was evaluated on the periorbital, perioral or full face area. 17 patients with phototypes II, III, IV and with Fitzpatrick Elastosis Score (FIS:1-9) received one to three treatments at 4-week interval.

All treatments were performed without topical anesthesia. Patients applied a healing cream (Ialucel™) several times a day, for 3 days after treatment. Physicians graded the level of improvement using pre and post-treatment photographs. Edema, redness and crusting were evaluated at 1, 3 and 7 days post treatment. Pain (scale: 1-4) and Fitzpatrick's score reduction have been also evaluated.

Results and Conclusions

17 patients (16F & 1M; mean age: 56 ±7) were treated on different locations with 3 different densities of microspots/cm². Duration of edema, redness, microcrusting and pain during the treatment are reported in figure 3.

Before treatment, the Fitzpatrick's score was 4.8 ±2.2 for density 100, 4.9 ±2.1 for density 150, 7 ±1.0 for density 200. At 3 month follow-up, the Fitzpatrick's score was reduced to 4.5 ±2.6, for density 100, 4.0 ±1.7 for density 150 and 5.5 ±0.7 for density 200. This reduction was found to be density dependent (fig. 4). Thanks to air cooling pain level was moderate.

This clinical study confirms that fractional resurfacing with this CO₂ laser combined with air-cooling is a safe and efficient and the improvement is better with highest density.

Figure 1: Post-treatment aspect
 Photo showing skin appearance after treatment at density 100 per/cm².

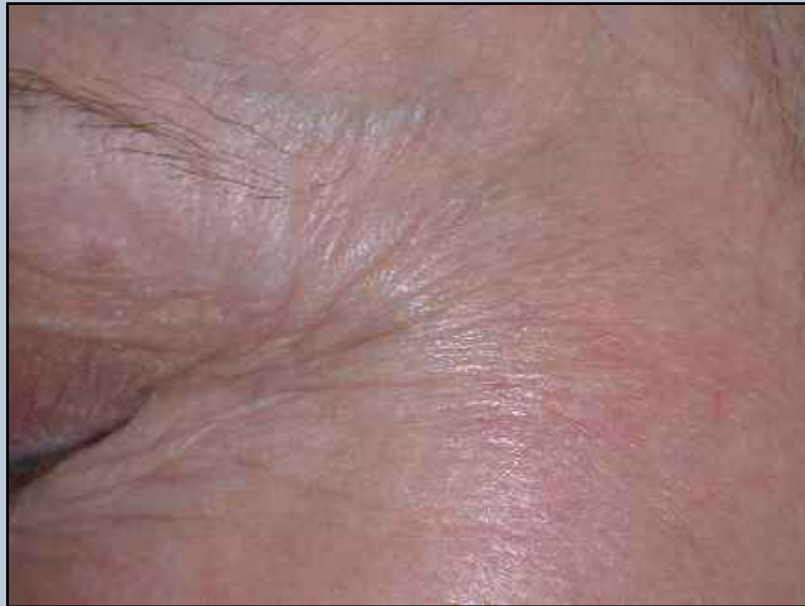Figure 2: Histological view of ablative and thermal effects of the treatment
 Photo showing histological view of the treatment effects.

Figure 3: Side effects and results on Fitzpatrick score as function of microspots/cm²
 Bar chart showing side effects and Fitzpatrick score reduction for different densities.

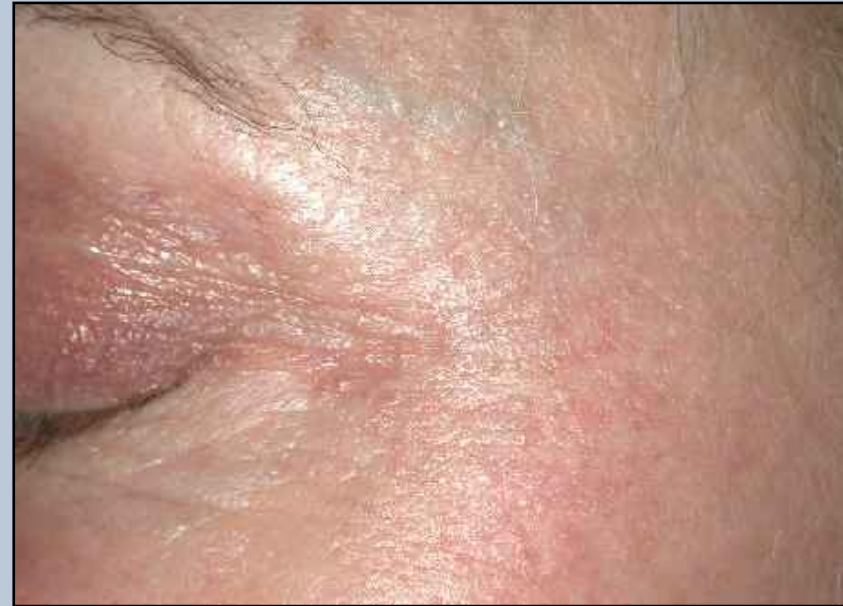Figure 4: Before and 13 months after 2 treatments
 Photo showing skin improvement before and 13 months after treatment.

Contact : Sylvie Angel, sylvie.angel1@wanadoo.fr

Resultados clínicos... periorbital




Antes

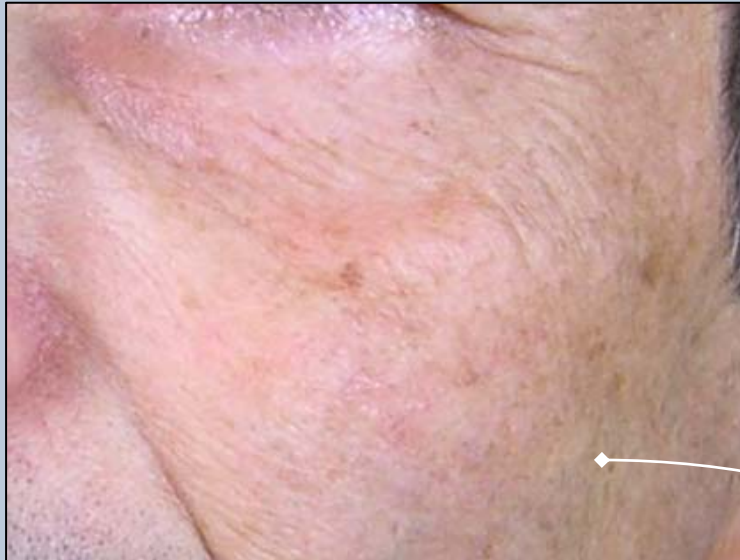

1 mes después de la 1era sesión

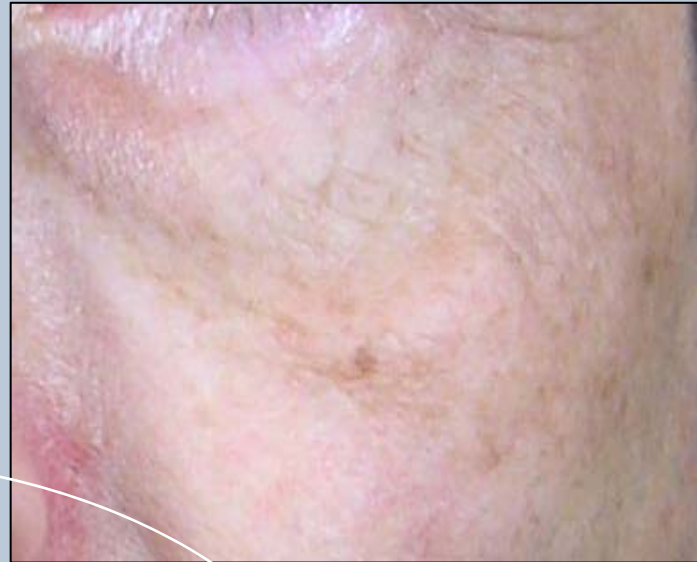Photos courtesy of J.L. Levy, MD



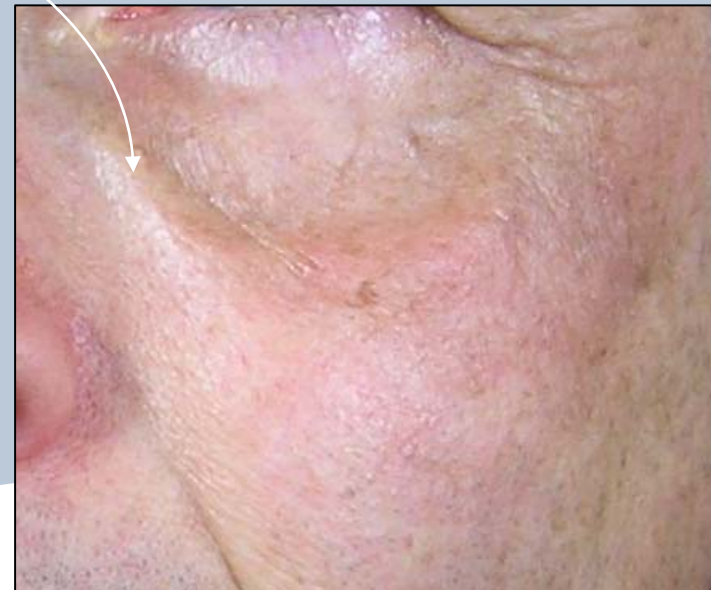Resultados clínicos... periorbital



Antes



Después de una sesión

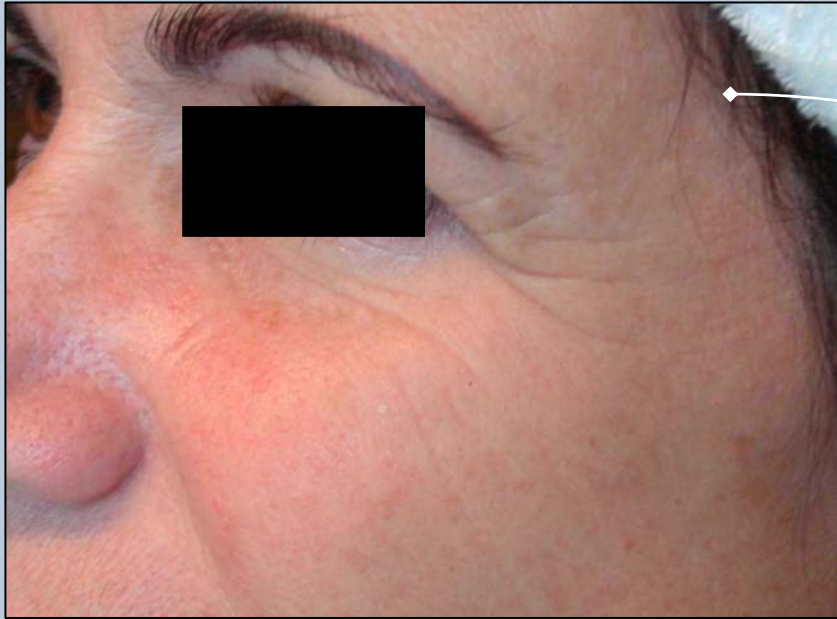

3 meses después de 3 sesiones

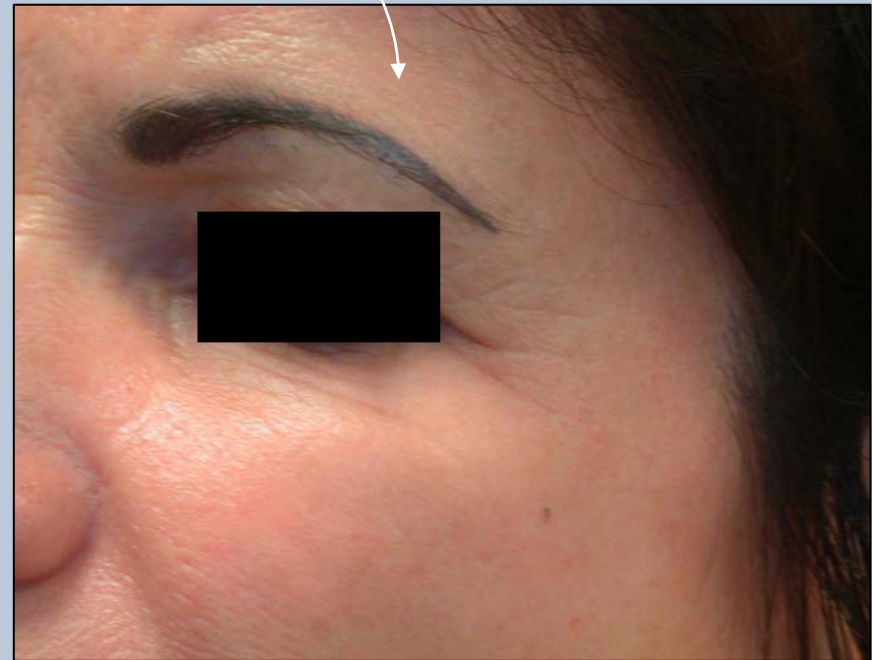Photos courtesy of S. Angel, MD



Resultados clínicos... periorbital




Antes

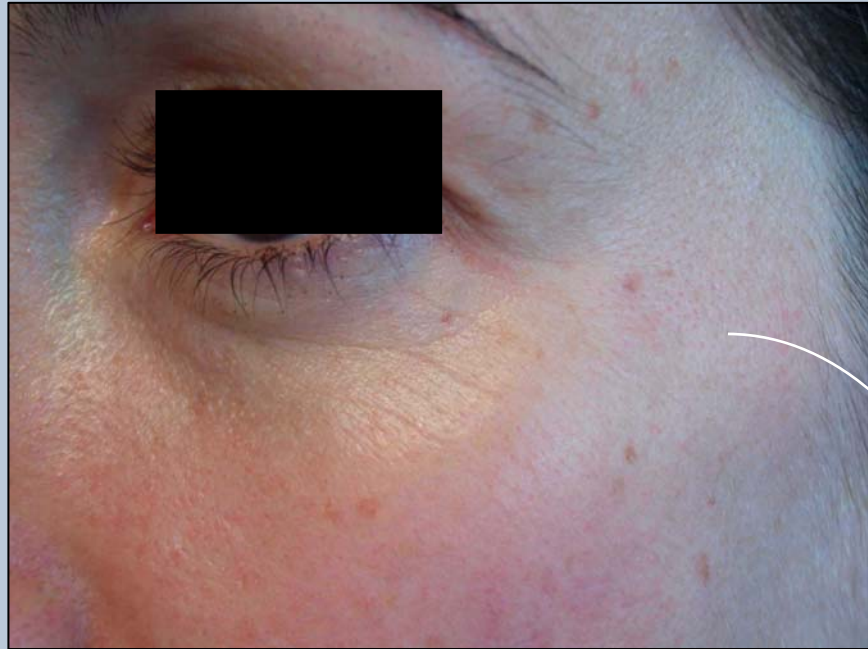

**14 meses
después de 1
sesión**

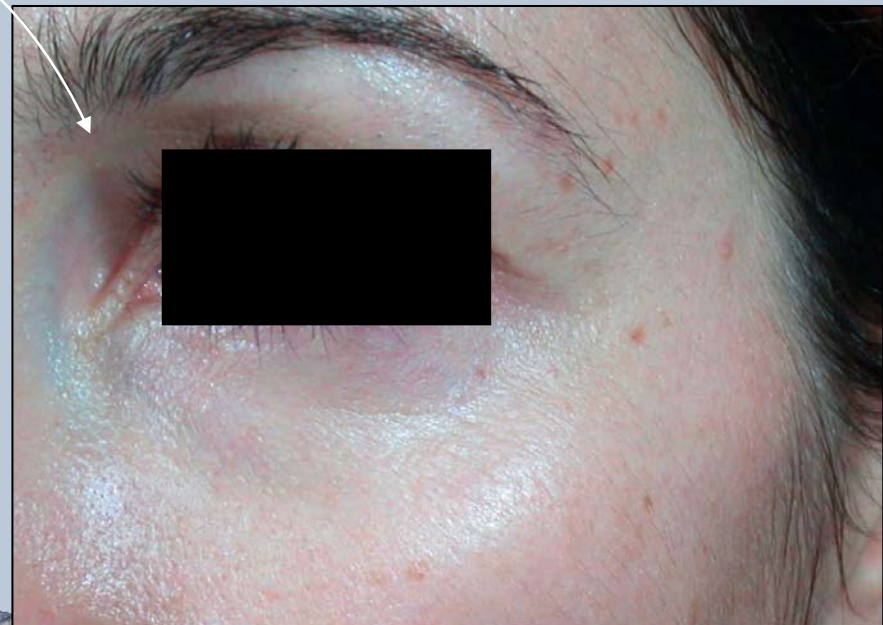Photos courtesy of S. Angel, MD




Resultados clínicos... periorbital



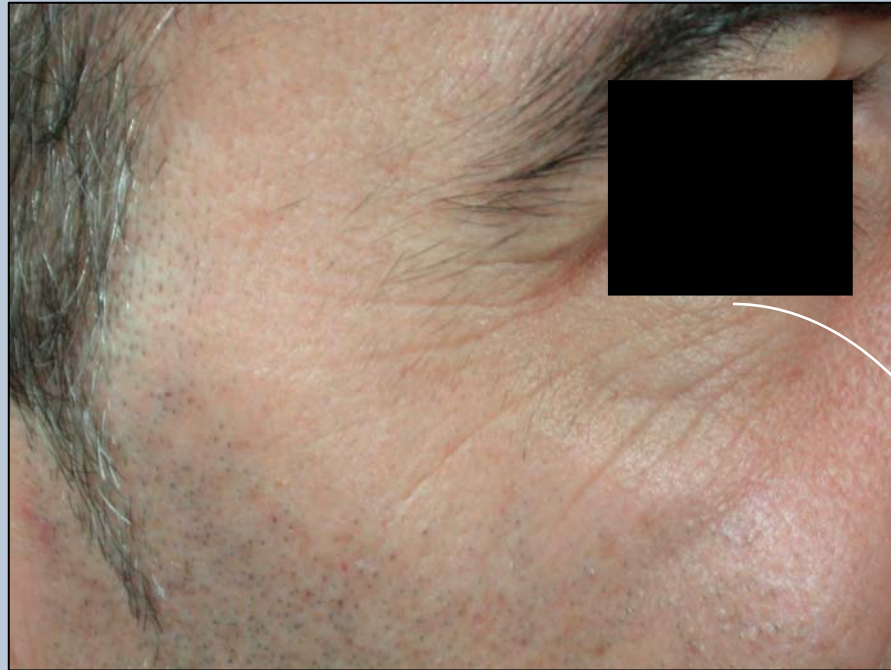
Después de 2 sesiones y 3 meses de seguimiento



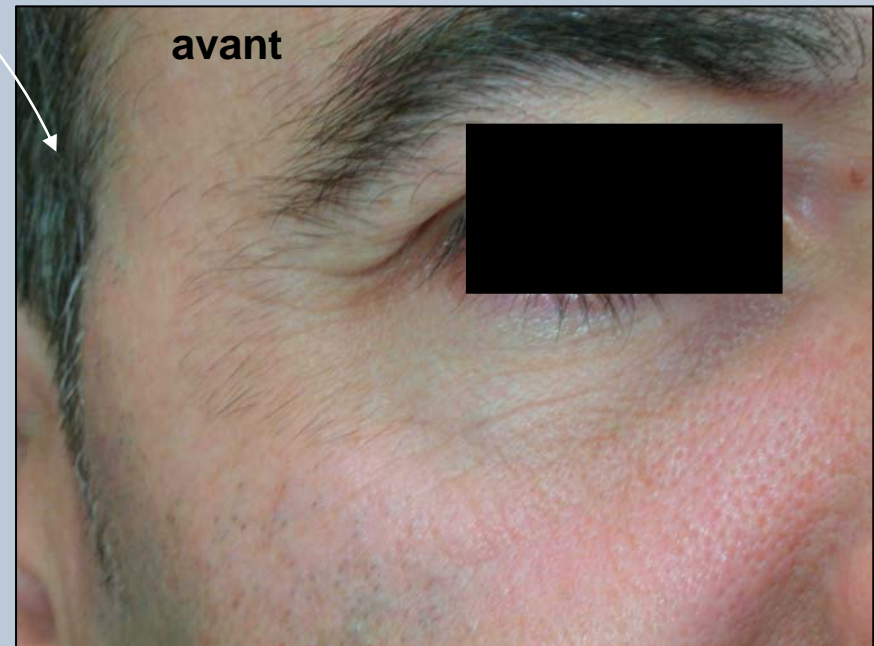Photos courtesy of Boineau, MD




Resultados clínicos... periorbital



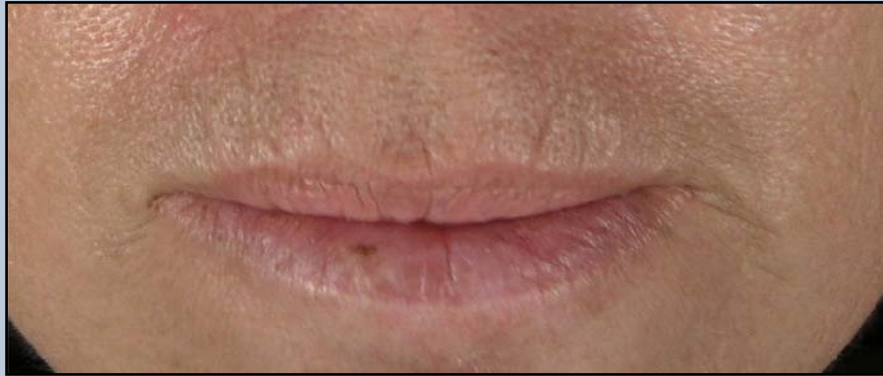Después de 2 sesiones y 18 meses de seguimiento



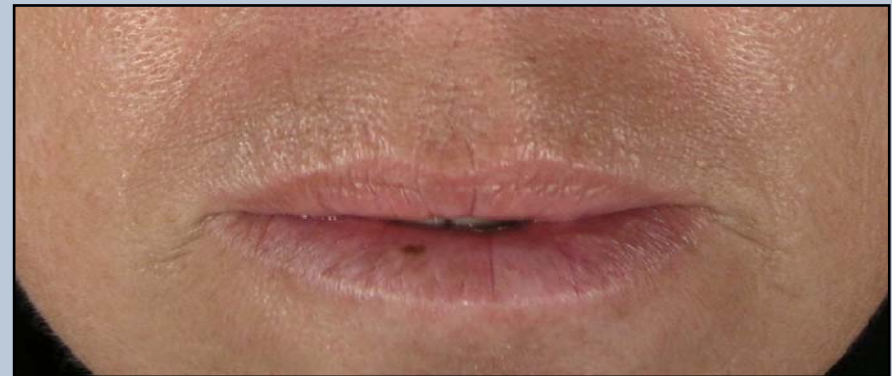Photos courtesy of Boineau, MD



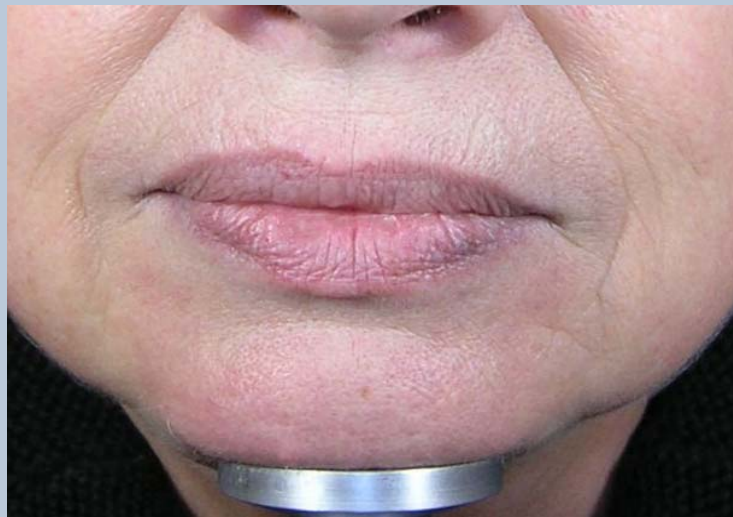Resultados clínicos...Períbucal



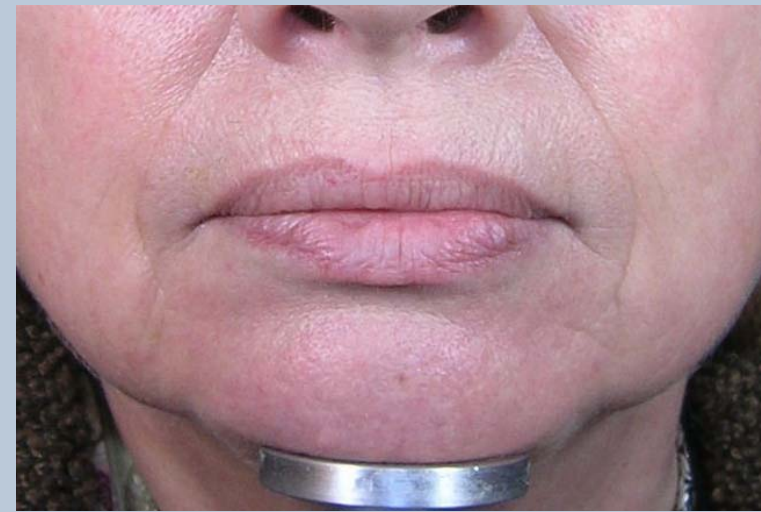Antes



3 meses después de 3 sesiones



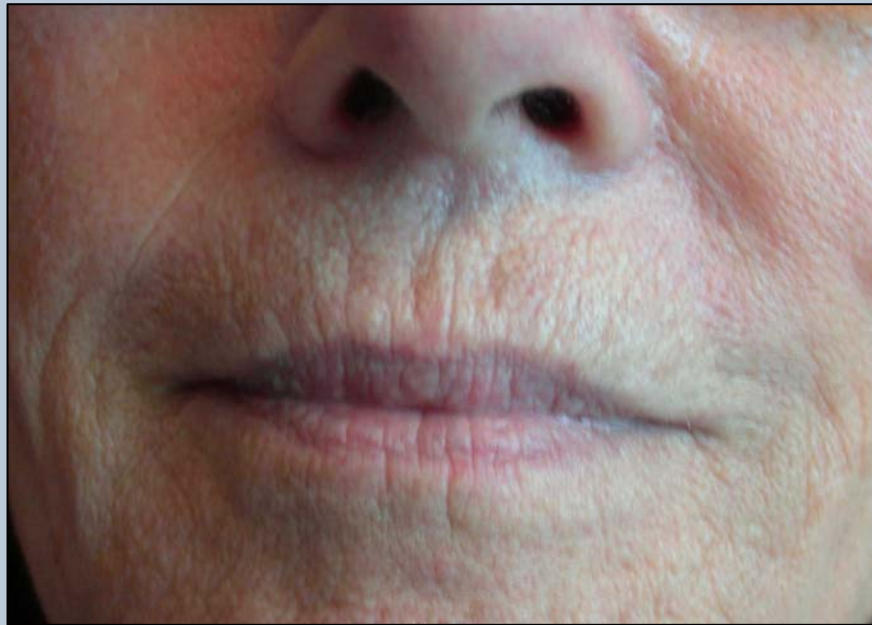Photos courtesy of S. Angel, MD



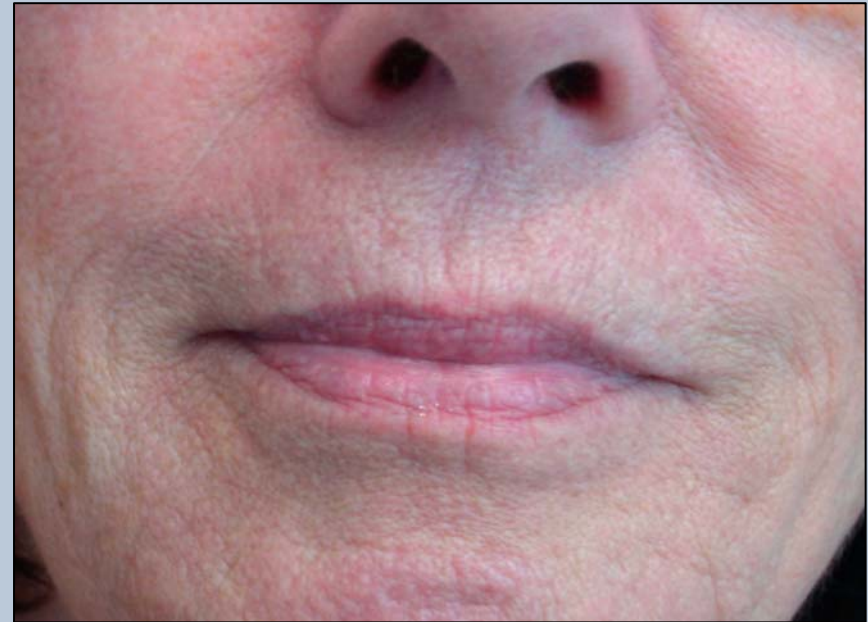**3 meses después de 2
sesiones suaves
150ptos/cm2**



Resultados clínicos...Períbucal




Antes

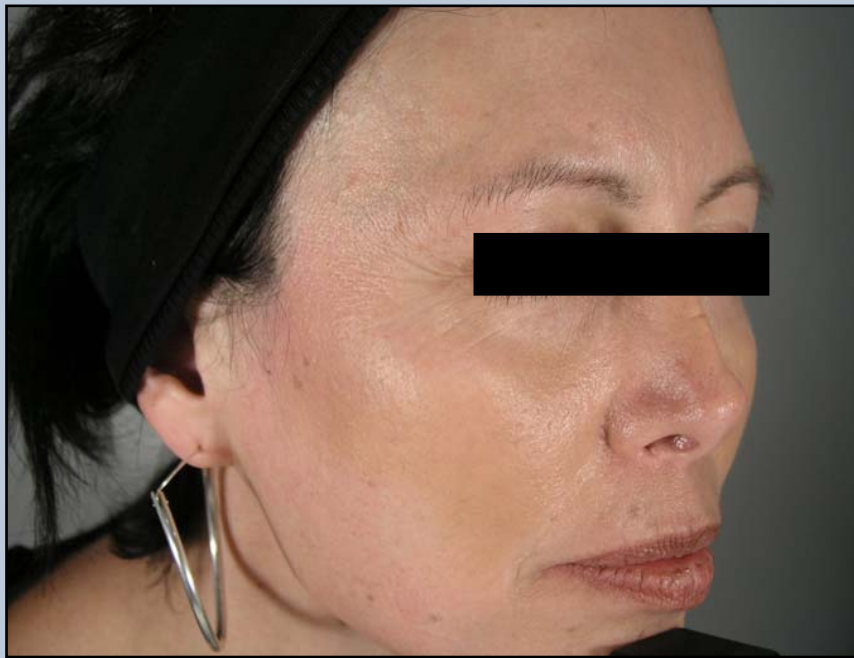

**3 meses después de 3
sesiones medianas
250ptos/cm2**

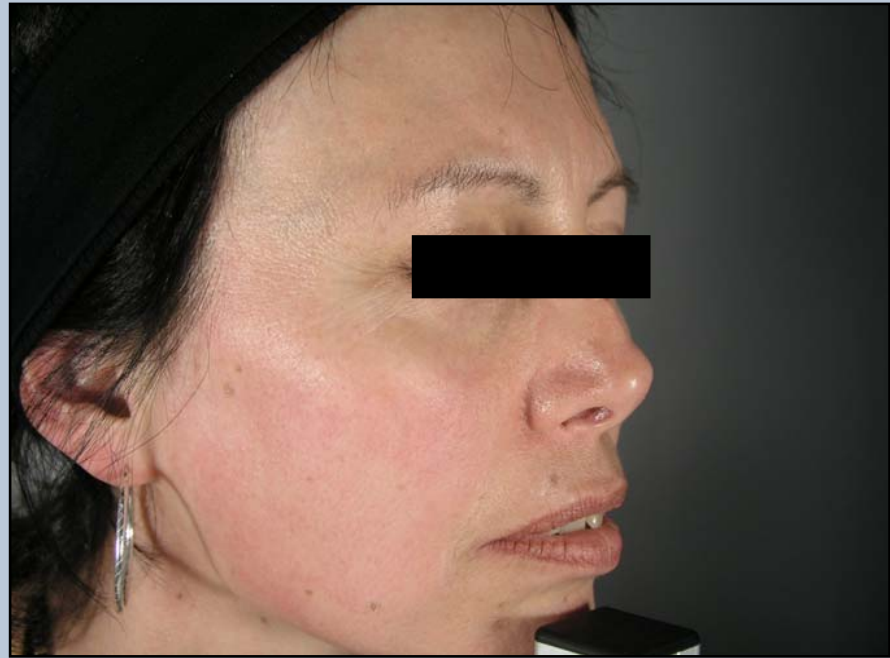Photos courtesy of Boineau, MD



Resultados clínicos... Facial completo




Antes

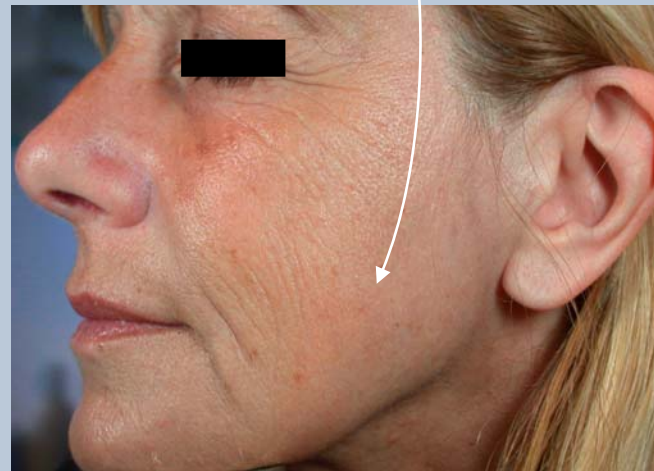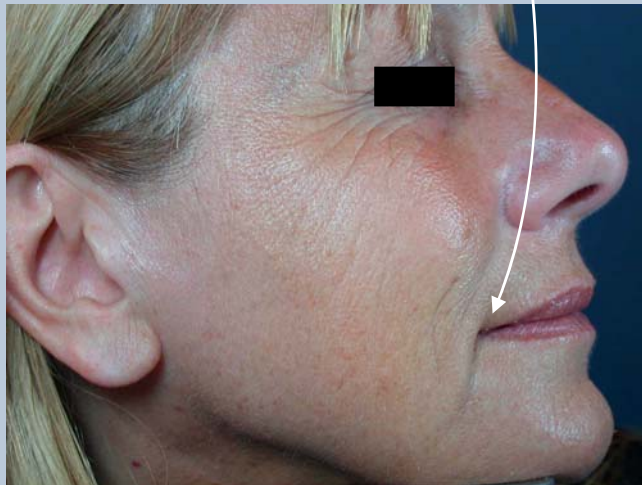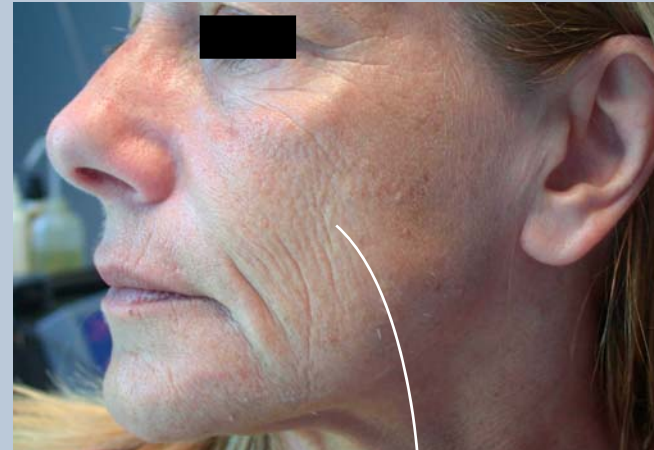


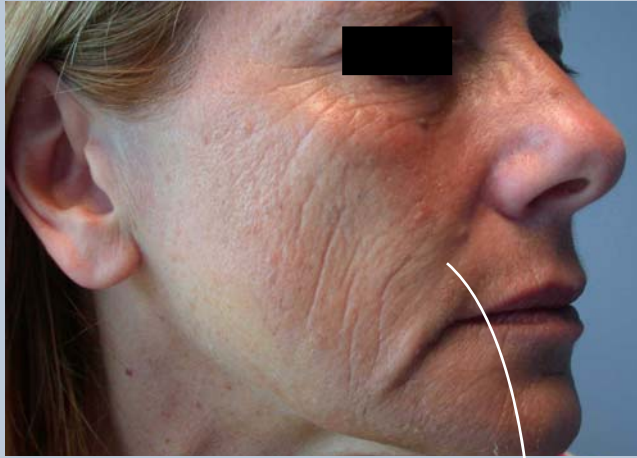3 Semanas después de la 1era sesión

Photos courtesy of D. Boineau, MD



Resultados clínicos... Facial completo

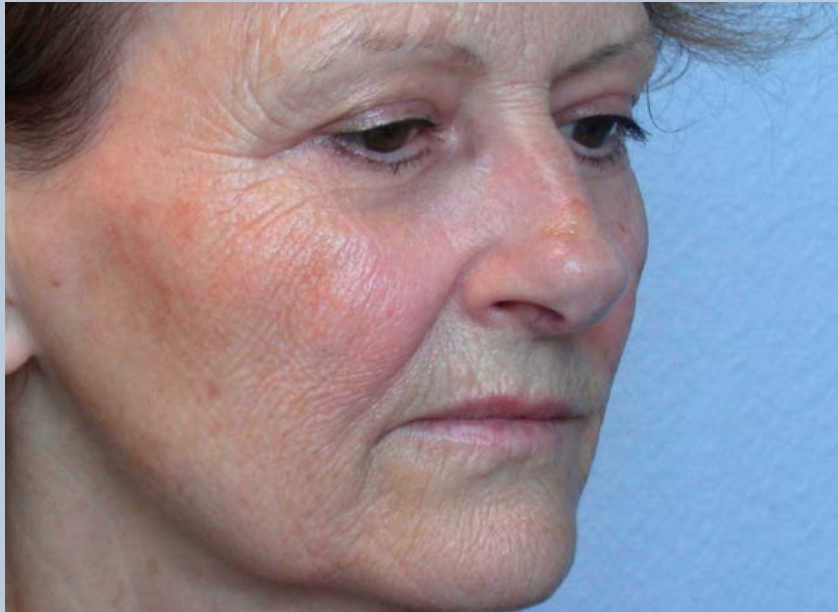

Photos courtesy of D. Boineau, MD

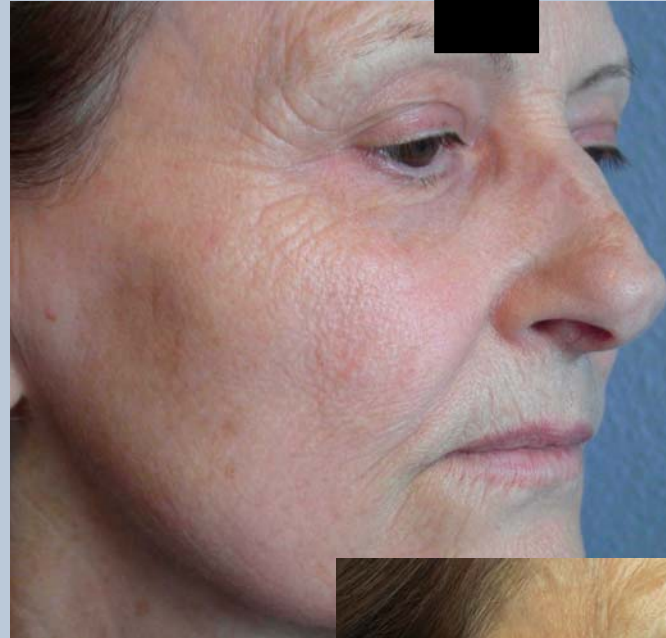**Después de 2 sesiones y
8 meses de seguimiento**



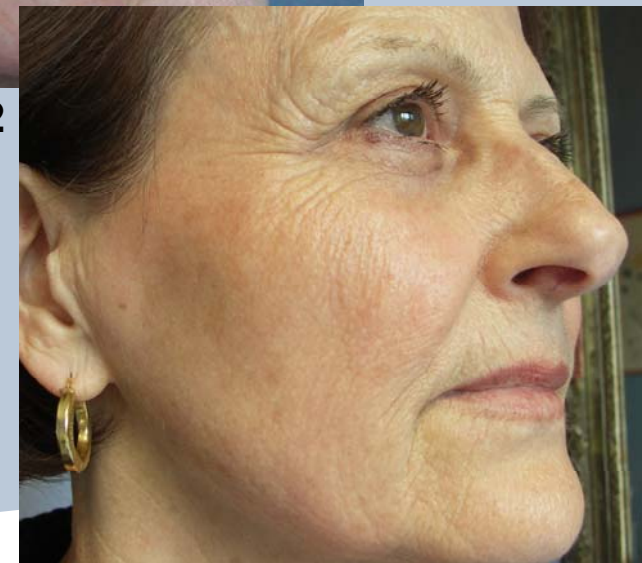Resultados clínicos... Facial completo



Antes




3 meses después de 2 sesiones

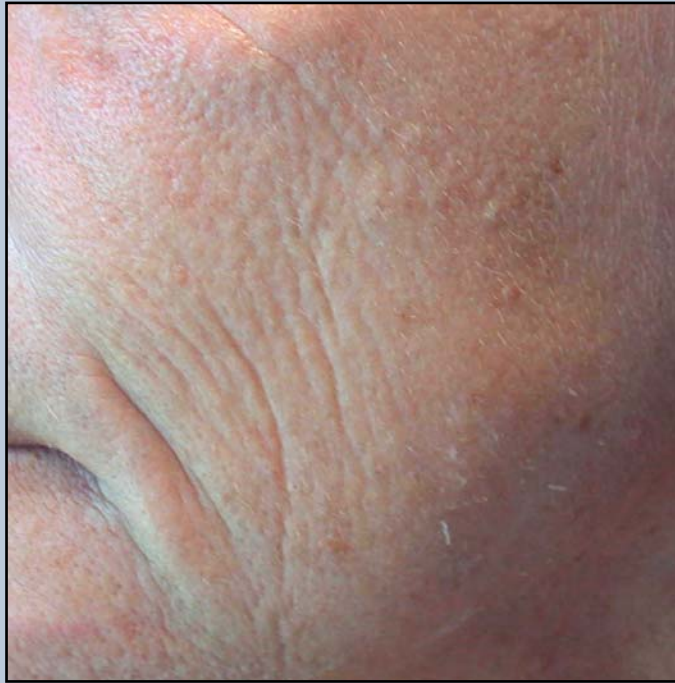

5 meses después de 3 sesiones

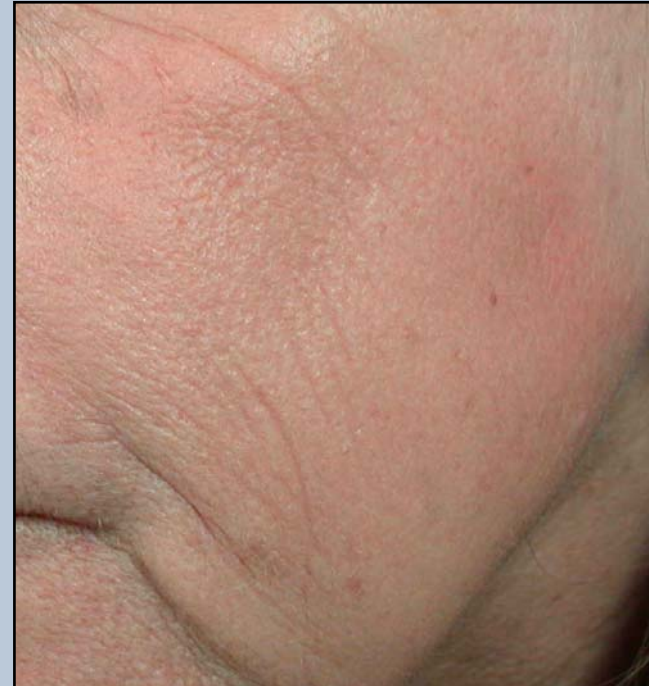Photos courtesy of D. Boineau, MD



Resultados clínicos... Facial completo




Antes

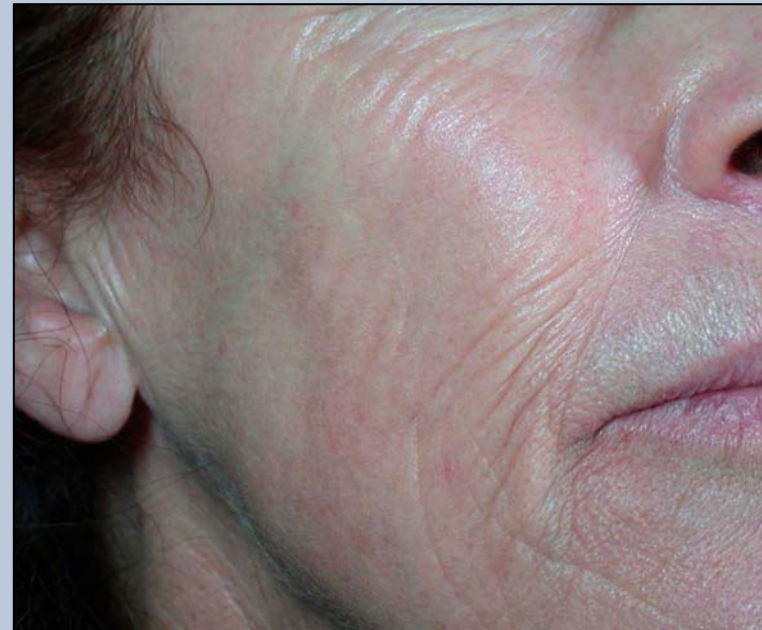
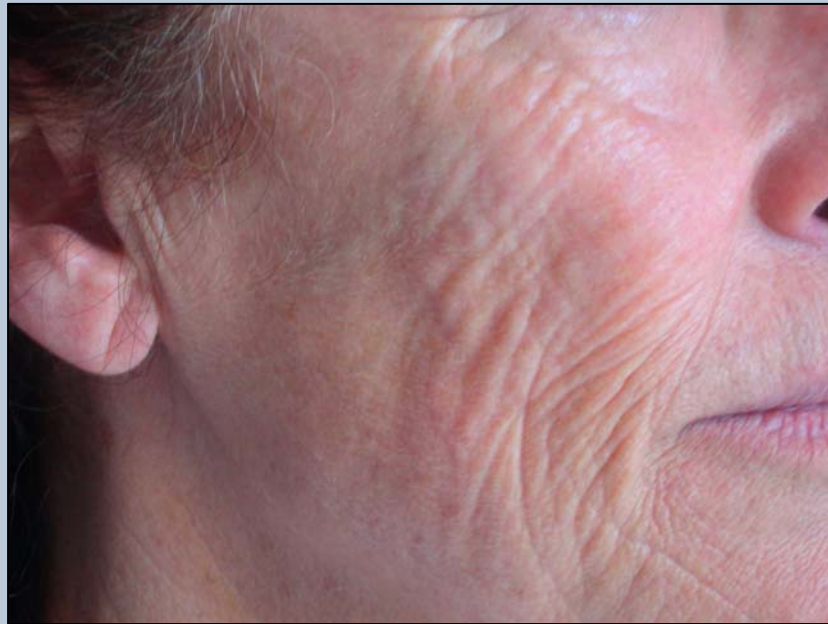
1 mes después de 1era sesión

Photos courtesy of D. Boineau, MD




Resultados clínicos... Retracción cutánea

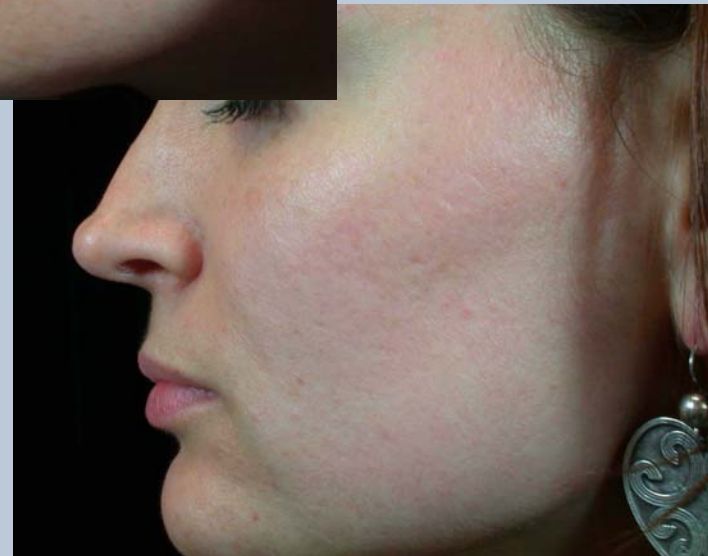
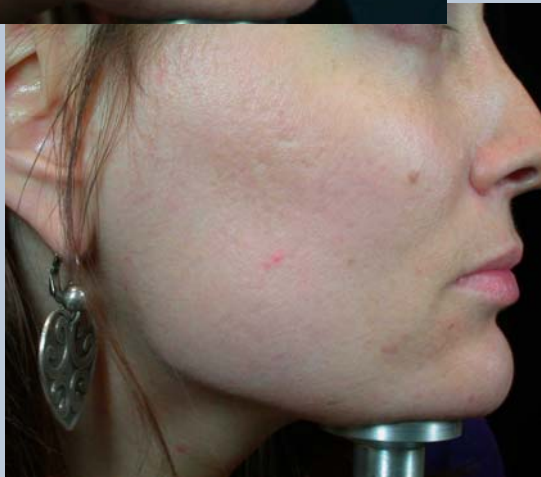
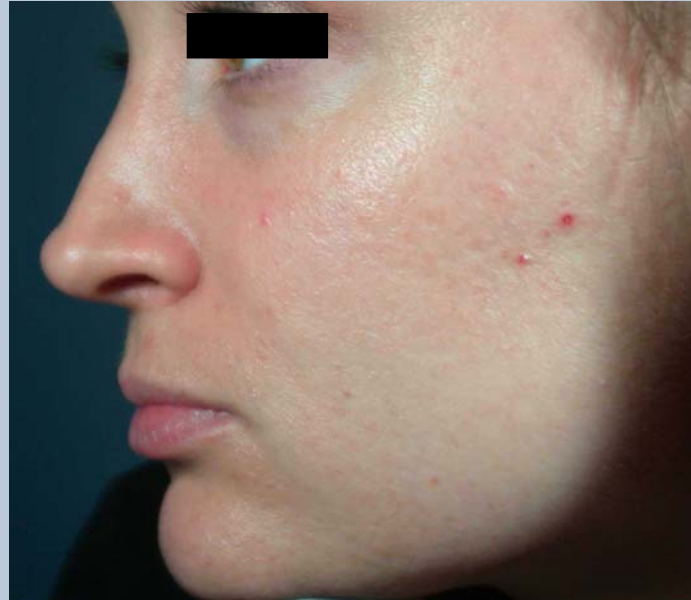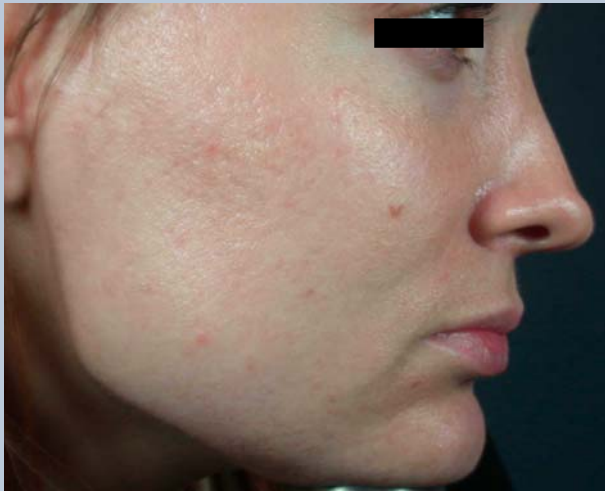2 sesiones con solo
10w@2ms 150ptos/cm2


Photos courtesy of D. Boineau, MD



Resultados clínicos... Cicatrices de acné

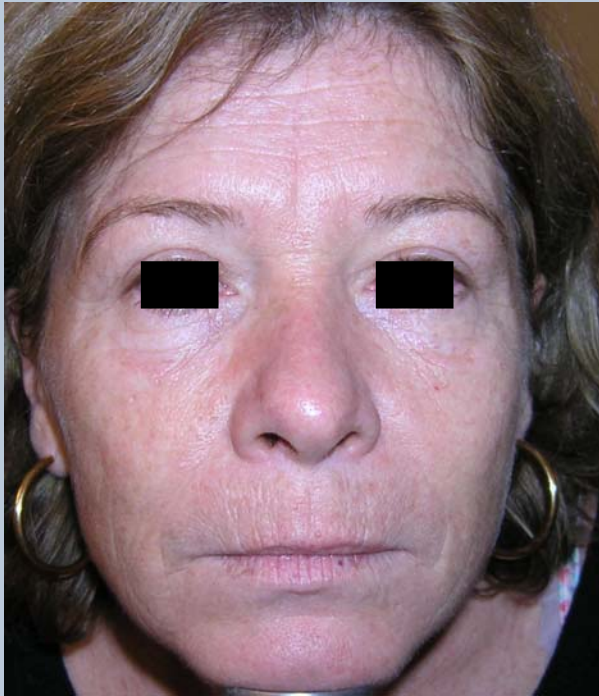

Photos courtesy of D. Boineau, MD

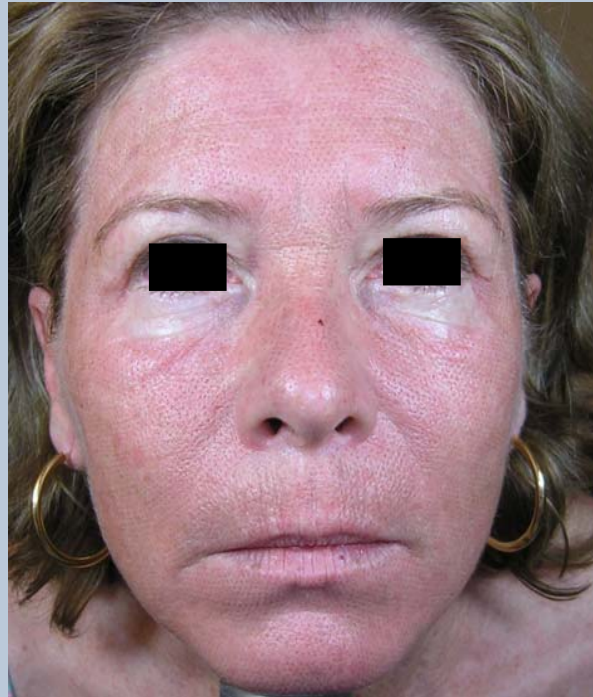

2 sesiones con solo
10w@2ms 250ptos/cm²

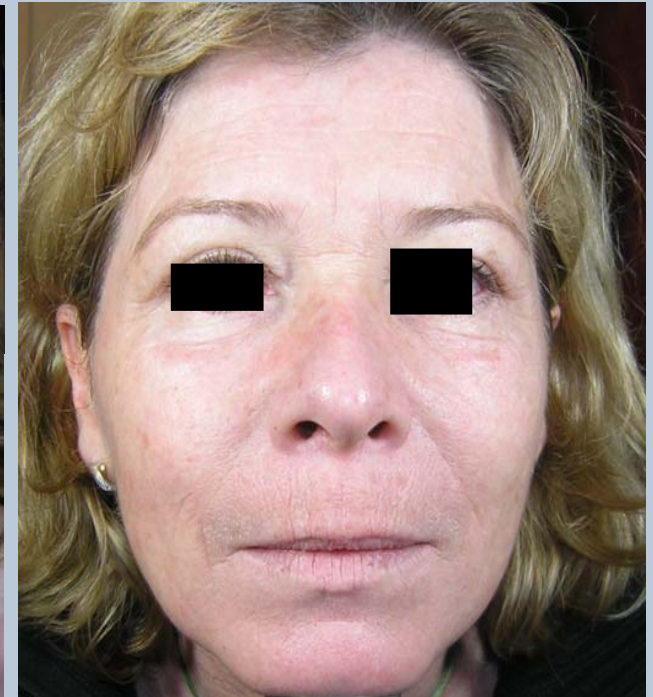... Efectos secundarios



Antes




Inmediatamente
después



10 días
después

Photos courtesy of D. Boineau, MD



Para más información no dude en llamarnos

EXELO₂



902 29 30 29

<http://www.cinlaser.com>

